

CASE STUDY EXAMPLE

INTRODUCTION

Craniosacral Therapy is a gentle, hands-on form of manual therapy which addresses dysfunction within the craniosacral system, which follows the movement and flow of cerebrospinal fluid within the ventricles of the brain, the dural tube, and the central nervous system surrounding the spinal and cranial nerves. The therapist uses specific techniques to help restore physiological balance of the nervous system, the brain and cranial bones. Homeostasis is restored to the patient through restoring optimal functioning of these areas. When restriction or dysfunction in these areas has been corrected or relieved, a patient may also experience an improvement of their physical, mental, emotional and spiritual well-being. Dr. John E. Upledger, founder of Craniosacral Therapy, has written multiple accounts where this has occurred, e.g. *Craniosacral Therapy II: Beyond the Dura* (Upledger, 1987); *SomatoEmotional Release and Beyond* (Upledger, 1990); *Craniosacral Therapy: Touchstone for Natural Healing* (Upledger, 2001); *Your Inner Physician and You* (Upledger, 1997). Within these texts Dr. Upledger has described numerous case examples from his osteopathic practice about how Craniosacral Therapy treats not only the physiological symptoms of disease but also the emotional components that contribute to and aggravate an injury, symptom or illness. Thus he and other practitioners of this method recognize there is a strong correlation between the physical and emotional aspects of dis-ease. They stipulate that therapists need to consider the emotional implications of recurring chronic pain, injury or illness and explore what may underline any resistance to the healing process.

Scientific research studies of this genre continue to be challenging. Emotional energy is unique to each individual situation and experience, therefore it is difficult to measure and quantify. It is stipulated here that emotion may not always play a direct part in the healing of a physical injury, as many physical injuries are able to resolve with a prescribed form of treatment on a physical level. However this case study seeks to describe and explain what occurred with a patient who had a “simple” orthopedic injury that did **not** recover after following the prescribed physical therapy technique. An unexpected review of the historical memory of the occurrence that was underlying the injury provided an opportunity for the patient to release the emotional content of a painful personal loss experience. This ‘meaning making’ provided a relevant backdrop to the history and content of their injury. In the patient’s mind once they were able to emote and make ‘meaning’ of their experience they were able to identify the root cause of their chronic injury and subsequently made remarkable improvements.

HISTORY

This case involves a 38 year old adult female who presented, to this author and therapist, with a chronic 2nd degree left ankle sprain. It had occurred in November 2002 when she stepped awkwardly off of a street curb and twisted it 11 months prior to this therapeutic experience. This patient is a successful

trial attorney who enjoys running as a stress-relieving, leisure activity. She is an intelligent, self-proclaimed “left brain, linear thinker” who deals in facts and statistics. She was a recently divorced mother of two at the time of her initial visit. Although her job does confine her to a desk at times, it also requires a lot of activity as well, which includes standing for long periods of time. She presented in excellent health, with no other significant medical history, nor previous ankle injury. Except for the Caesarean births of both of her children, she had never undergone any previous surgical procedures. The patient reported being happy and content in her life, and stated that she enjoys an active lifestyle that involves sports, cooking and travel.

Upon initial onset of the injury, the patient stated that pain and swelling of her left ankle had occurred immediately and that she was initially unable to bear weight on her left foot. She sought medical attention at a local hospital emergency room. X-rays were negative and physical assessment determined soft tissue damage to the lateral aspect of her ankle. She was initially treated with ice, an ace wrap, crutches and mild pain medications (Tylenol with codeine). She was instructed to continue ice applications, elevate when possible and two weeks later was referred to physical therapy. Traditionally-based physical therapy was conducted for 2 months, three times per week consisted of ice, whirlpool bath, ultrasound treatments, exercise and ambulation skills. The patient progressed, was eventually able to ambulate without an assistive device and regained some of her ankle range of motion, but continued to complain of ankle tightness and intermittent pain when engaging in activities such as running, stair climbing and prolonged periods of standing. These activities could also produce minor ankle swelling on occasion if she did any of them to an extreme or repetitively. She would ice her ankle when this occurred although she had stopped the prescribed medication after the initial two week period.

TESTS AND MEASUREMENTS

After 9 months without any formal treatment, the patient was referred to this therapist. She stated that her ankle felt “85% healed” but was seeking a 100% recovery. Upon initial evaluation, pain was elicited mostly with manual pressure applied at the extreme ends of the available range of motion. On a 0-10 scale, the patient stated it was a 5. She also stated that her ankle pain could increase to a 7/8 with the aforementioned activities. There was minor tenderness upon palpation of the left lateral malleolus, and no visible edema was present.

Goniometric measurements to determine available range of motion were as follows:

Dorsiflexion- Active: 10 degrees Passive: 20 degrees

Plantarflexion – Active: 25 degrees Passive: 28 degrees

Inversion – Active: 10 degrees Passive: 20 degrees (with pain level of 5)

Eversion – Active: 10 degrees Passive: 10 degrees (with pain level of 5)

A standard Manual Muscle Testing procedure was performed to assess the patient's ankle strength. The patient was placed lying on a table; applicable positions were assumed to ensure that each motion was against gravity when resistance was applied. The results were as follows:

Dorsiflexion – 4 (good)

Plantarflexion – 4 (good)

Inversion – 3 (fair)

Eversion – 2+ (poor plus) – with pain elicited at the end of the range, level 5 on the 0-10 scale

Evaluation of the patient's gait showed no obvious deviations, although she subjectively stated that her ankle felt "tight and stiff". The patient was successfully able to stand solely and balance well on her left foot. She was able to perform "darting" motions and quickly change directions when instructed to, although reported a pain level of 5 on a scale of 0-10 when doing so. She could also perform such activities as hopping and skipping, but with discomfort after repetition over one minute, citing a pain level of 3 on a scale of 0-10.

TREATMENT

With the patient exhibiting good ankle strength and high-functioning ADL's, the treatment plan commenced with a focus on increasing the limited range of motion. Suspecting possible joint capsule swelling or inflammation, ice treatments were also applied. Manual strength exercises, based on PNF (proprioceptive-neuromuscular facilitation) patterning techniques, were also employed to upkeep the patient's lower leg muscular strength, as well as supporting any gains in range of motion. The basis for treatment rationale was the standard, documented physical therapy protocol for such an injury and the symptoms presented. The goal was to increase the patient's range of motion to normal and see a resultant decrease in pain level.

After 3 weeks, 3 times per week, for 45 minutes treatment sessions of the above treatment plan only minimal changes were observed. Trace degrees of range of motion were noted improved, in dorsiflexion and plantarflexion only. The patient subjectively reported no change at all in her pain levels.

Seeking other possible treatment options, this therapist, who is trained in Craniosacral Therapy, commenced with the "Direction of Energy" or "V-spread" technique (Sutherland, 1930; Upledger 1986). The left ankle of the patient was held passively between the therapist's hands. The therapist directed 'energy' from one hand through to the other hand. This technique was employed for 30 minutes during one treatment session. Tissue release signs demonstrated during this technique were heat and a "Therapeutic Pulse" (pulsing sensations, faster than a normal pulse which may describe a positive tissue response to circulation). These were noted in the ankle bone area during the treatment technique described. A brief reevaluation of the patient's ankle at the end of the session showed no significant change in the original objective findings, however the patient subjectively reported that the ankle "felt a little looser".

The patient returned for her next session two days later, reporting that after the last treatment session she felt she had finally started to see some improvement, but that her ankle was still not 100%. She stated that her ankle did not feel as stiff as it had previously. Objectively, there were still no measureable increases in range of motion.

With the patient lying supine, treatment commenced once again with the 'Direction of Energy' technique in the exact manner as the previous session. Several minutes into its application, the patient's ankle began to gently move as tissue spontaneously began "unwinding". The 'Regional Tissue Release' technique was used to follow and support this process. The patient's mood was upbeat, and a light conversation between patient and therapist ensued. Several more minutes into the treatment, the patient grew quiet. It was noted that this was concurrent with a stopping of her Craniosacral Rhythm (CSR), otherwise known as a 'Significance Detector'. This indicated that the patient's body was experiencing a significant therapeutic occurrence. Within the next 2-3 minutes, the previously upbeat patient began to sob quietly. The therapist held a respectful presence for the patient's therapeutic process while continuing with the 'Direction of Energy' technique.

A few minutes later, the patient spoke and started to tell the story of her ankle injury in more depth than she had previously. When the injury was sustained, the patient had stepped off of the curb that was directly in front of the courthouse where she had just finalized her divorce from her now ex-husband. She stated that she had never cried or emoted in any way regarding this life-changing event. She was surprised to find herself so moved to release these emotions at this time. The patient's emotional release and story recantation lasted approximately 15 minutes in total. Her Craniosacral Rhythm restarted after sharing this story. 'Regional Tissue Release' of her ankle resumed for approximately 5 more minutes before the session was completed.

The patient returned after 3 days time, reporting a marked improvement in her ankle symptoms. She stated that for the first time since her injury, she had been completely pain free all weekend. The usual tight stiffness she experienced was also gone. She stated that she had not done anything out of the ordinary in the previous 3 days, except that because her ankle felt so good, she had gone for a long run; something that previously would have caused her more pain and probably swelling, neither of which occurred.

The patient also apologized for crying and stated that she could not believe that she had gotten so emotional during the last session. She said that she had left feeling "lighter, happier and with a sense of relief". The therapist reassured her that this was not inappropriate to the session. When the discussion turned to the concept of a physical and emotional injury connection, the patient stated that although her left brain had a hard time grasping it, she felt that that explained exactly what had happened with her ankle healing.

Subjectively, the patient reported a 0 on the pain scale of 0-10 in all of her ADL's, including standing for extended periods of time, stair climbing, running and quick response "darting" movements. The patient stated that her ankle felt "like new again", and that "it felt 100%".

Goniometric measurements showed a significant improvement to normal ranges, for the first time in the patient's treatment term, in her ankle range of motion.

RESULTS

Goniometric re-measurements of available range of motion were as follows:

Dorsiflexion- Active: 15 degrees Passive: 20 degrees
Plantarflexion – Active: 30 degrees Passive: 35 degrees
Inversion – Active: 35 degrees Passive: 35 degrees (with no pain)
Eversion – Active: 15 degrees Passive: 15 degrees (with no pain)

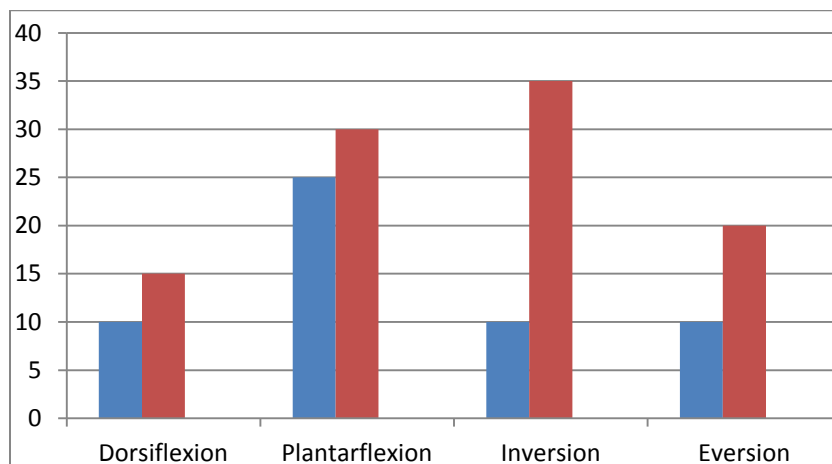


Fig. 1 Active Left ankle Range of Motion pre- and post-Craniosacral Therapy

Key : Pretreatment examination= blue

Post treatment examination = red

Manual strength testing also improved significantly.

Dorsiflexion – 5 (normal)
Plantarflexion – 5 (normal)
Inversion – 4 (good)
Eversion – 4 (good) – with no pain elicited

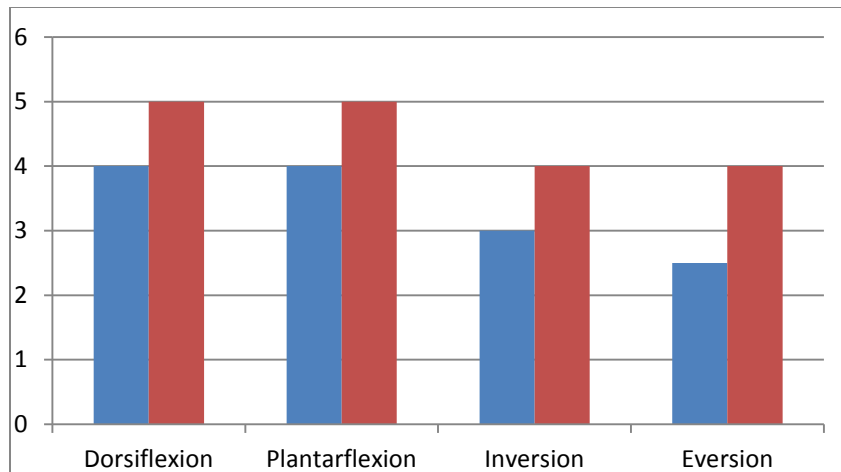


Fig. 2 Standard Manual Muscle Testing pre- (blue) and post-craniosacral therapy (red)

Subjectively, the patient reported a 0 on the pain scale of 0-10 in all of her ADL's, including standing for extended periods of time, stair climbing, running and quick response "darting" movements. The patient stated that her ankle felt "like new" again, and that it "felt 100%".

DISCUSSION

Patients with ankle sprains are not traditionally treated with Craniosacral Therapy techniques. Most commonly such orthopedic and sports injuries are treated with the standard physical therapy protocol of exercise, ultrasound, cold and/or heat. To further the discussion, it appears that full recovery was not wholly, or at least readily, attained without the release of the emotional component that related to this patient's injury.

Whereas the connection of emotion to a physical injury may be purely objective, the concept is clearly described with clinical examples in such references as *SomatoEmotional Release and Beyond* (Upledger, 1990). This book, as well as other literature such as Alice Lindsay MS, LMT, CST-D's *SomatoEmotional Release: A Whole-Person Treatment* (Dade Palms, 2006), retells countless treatment encounters where patients have spontaneously (meaning with no conscious forethought by therapist or patient) emoted during treatment. With varying degrees, both positive subjective and objective improvements have resulted. One may choose to call this coincidence, but the frequency of occurrence and significant results afterward may lead this to be a naïve conclusion. The inherent difficulty in measuring and quantifying such outcomes is wherein the problem lies. How do we measure emotion and its connection to the healing of physical injury? How do we differentiate physical and emotional energy, and the affect each may have on the healing process?

To date, anecdotal evidence is our most powerful voice in support of this concept. It is not the premise of this case study to infer that *all* injuries, ankle or otherwise, necessitate emotional release for full recovery. The numbers of cases where orthopedic injuries have fully healed without emotional release are countless. On the contrary, it is stipulated, however, that the unsolicited, spontaneous release of

subjective emotion while physical treatment is underway, may be necessary in some cases for full healing to take place. The basis of the criteria, however, is to date determined, and seemingly prompted by, the patient's own non-conscious awareness in some way. Further case documentation and study of this little-explored territory of healing is highly recommended.

REFERENCES

- Upledger, John E., D.O., F.A.A.O. (1983). *Craniosacral Therapy*. Seattle, WA: Eastland Press.
- Upledger, John E., D.O., F.A.A.O. (1987). *Craniosacral Therapy II Beyond the Dura*. Seattle, WA: Eastland Press.
- Upledger, John E., D.O., O.M.M. (1990). *SomatoEmotional Release and Beyond*. Palm Beach Gardens, FL: UI Publishing, Inc.
- Peeling, Becky, APR. (2003, Spring). Craniosacral Therapy: Following the Body's Cues. *Spa Life*, 12(2), 93
- Lindsay, Alice (Ali) D., MS, LMT, CST-D. (2006, Summer). SomatoEmotional Release: A Whole-Person Treatment. *Dade Palms*, 12. Retrieved from <http://www.fsmta-dade.org>
- Upledger, John E., D.O., O.M.M. (1997). *Your Inner Physician and You*. Berkeley, CA: North Atlantic Books
- Upledger, John E., D.O., O.M.M. (2001). *CranioSacral Therapy: Touchstone for Natural Healing*. Berkeley, CA: North Atlantic Books

Improved chronic ankle injury results from V-spread tissue release and spontaneous emotional release.

Author(s) name(s): i.e. John Jones, MS, LMT and Sally Smith, PTA

Author(s) Affiliation(s): i.e. *University of New Mexico Medical Center*

Abstract

A case study of a 38 year old female who sustained a 2nd degree ankle sprain is treated with traditional physical therapy applications of ice, ultrasound and exercise for a duration of 2 months with some symptom improvements . Eleven months later, continued ankle pain and symptoms causes her to seek further treatment to recover more ankle flexibility and stamina. After more traditional therapy techniques and no change, therapist offers Craniosacral technique of V-spread, Direction of Energy. This treatment subsequently elicits an emotional release of relevant history that explains more of the injury and its recurring symptoms. On release of emotions and 'meaning making' by patient, they experience a full recovery of all ankle functions, strength and movements This case study provides supportive evidence that some injuries may have both a physical and emotional component . In order for these injuries to heal, both the physical and emotional content of the injury need to be addressed and released.

Key words: *Craniosacral Therapy, chronic ankle sprain, emotional release, Direction of Energy, Regional Tissue Release*